

Clinical revision for OSCE examinations

Please note that these notes cannot be printed

© Copyright 1994-2009 Academic Medical Publishing.

Tudor Lodge, Roseworth Crescent, Newcastle upon Tyne NE3 1NR.

First published 1994

Reprinted Annually 1995-2006

14th reprint - 2007

All rights reserved. No part of this publication may be reproduced, stored in a retrieval system, or transmitted in any form or by any means, electronic, mechanical, photocopying, recording or otherwise without the prior written permission of the copyright owner. Any breach of this copyright will lead to prosecution.

Whilst the advice and information in this book are believed to be true and accurate at the date of going to press, neither the author nor publisher can accept any legal responsibility or liability for any errors or omissions that may be made. Every effort has been made to check the drug dosages given in this book. However, as it is possible that some errors have been missed or that dosage schedules may have been revised and the reader is strongly urged to consult the drug manufacturers literature or the British National Formulary before administering any of the drugs listed in this book.

British Library Cataloguing in Publication Data

Dark, G. G.

How to pass finals, course notes.

1. Medicine.

I. Title.

610

Typeset and produced by Academic Medical Publishing.

Text set in Times New Roman; titles and captions in Arial.

Printed in UK.

Chapter 5

Clinical revision for OSCE examinations

THIS ENTIRE SECTION IS DESIGNED FOR REFERENCE PURPOSES ONLY.

In the preparation period before finals you should be able to perform a basic physical examination of each of the systems relevant to the exam and have an understanding of the physical signs that can be found during the examination and their significance. There is no substitute for clinical experience and you are best advised to examine as many patients as possible before the examinations start.

In this section there is a series of diagrams that outline suggested methods for the physical examination of patients, not only for exams but also for the real clinical situations of outpatient and casualty departments. The objective of the clinical diagrams is to optimise your physical examination routines such that signs relevant to the problem can be specifically sought in an organised manner, which appears impressive to the examiners. The concept of the diagram is to start at the bottom left hand corner and work up and around in a clockwise fashion. It is hoped that you find these of benefit and that as your examination routines become more polished, you begin to enjoy the challenge of achieving an accurate diagnosis. It is all a game and when you are more proficient, the game becomes easier and more enjoyable ! Medicine can be fascinating but only for those who are on the look out for interesting signs. If you don't look, you won't see !

How to use this clinical revision section

The best way of gaining benefit from this clinical revision section is to use it for reference after seeing a patient with a particular condition. After completing your physical examination of a system you are then encouraged to read the relevant page with the suggested method of examination for the same system that you have reviewed. This will attenuate and reinforce your learning and encourage recollection of the situation when faced with the same clinical problem in the future and may demonstrate specific points that were overlooked during your routine.

Example presentations of clinical findings are given for each system and you should practise using these as guidelines for other conditions that you encounter when examining patients on the wards during your preparation. A list of the more common conditions encountered in the short cases is included and you should become familiar with each of the conditions on these lists.

Specific advice for clinical examination is given with guidance to examination in the exam setting. Lists of causes of physical signs found on clinical examination should be consulted after seeing a patient with that specific condition. The arbitrary reading of such lists could be dangerous for your mental health if you do not have the mental image of a patient with which to associate it.

Finally, a series of learning objectives are listed at the end of each system section and can be used as a basis for your revision and preparation for the clinical examinations. Further space has been provided for you to add your own revision notes.

Examination of the cardiovascular system

Common introductory directives

Please examine this patient's cardiovascular system.
 Please examine this patient's heart.
 Please examine this patient's praecordium.
 Examine the cardiovascular system.
 Don't worry about the peripheral pulses, concentrate on the heart.
 This patient is short of breath, please examine the cardiovascular system.
 Listen to this patient's heart.
 Listen to the apex beat.
 This is Mr Smith, please examine the heart only.
 Assess the cardiovascular system.
 This patient has a problem with heart valves, please examine.
 Examine the cardiovascular system and talk me through it.
 Examine the JVP, apex beat and listen to the apex.
 This patient has recently had a myocardial infarct.
 Please examine the cardiovascular system.
 This patient presented with a transient ischaemic attack. Examine the patient to elicit a cause.
 Feel the pulse and listen to the heart only.
 Look at this patient (recent sternotomy scar) and examine whatever you think is relevant (CVS).

Suitable cases for cardiovascular examination

MORE COMMON

Atrial fibrillation
 Mitral incompetence
 Prosthetic valves
 Mixed mitral valve disease
 Mixed aortic valve disease
 Mitral and aortic valve disease
 Tricuspid incompetence
 Left ventricular failure
 Infective endocarditis

LESS COMMON

Raised JVP
 Mitral stenosis
 Eisenmenger's syndrome
 Atrial septal defect
 Ventricular septal defect
 Dextrocardia
 Complete heart block
 Pulmonary hypertension
 Coarctation of the aorta

Examination of the pulse

Irregular pulse
 Atrial fibrillation
 Slow pulse
 Aortic stenosis
 Complete heart block
 Collapsing pulse
 Brachial artery aneurysm
 Tachycardia
 Hypothyroidism
 Vascular access graft (for dialysis)

You are asked to examine the cardiovascular system

conjunctival pallor
Argyll Robertson pupils (AR)
lens dislocation (Marfans)
xanthelasma
arcus senilis
high arched palate
dental caries
central cyanosis

JVP: waveform, height
cannon waves (CHB)
carotid pulse: quality, volume
Corrigan's sign (AR)
De Musset's sign (AR)

blood pressure:
lying and standing
paradox (tamponade)

pulse: rate, rhythm and nature
? equal L & R

peripheral cyanosis
clubbing
nicotine stains
splinter haemorrhages
capillary pulsation (AR)
pallor
Janeway lesions/Osler nodes
arachnodactyly
xanthomas
rheumatoid changes
systemic sclerosis
palmar erythema

Inspection:
breathlessness/respiratory rate
sternotomy scars
mitral facies
pocycythaemia
ascites
abdominal pulsation
marfanoid appearance
myxoedema
Down's syndrome (ASD)
cushingoid appearance
anxiety

Inspection:
pectus excavatum/chest wall symmetry
left parasternal impulse
look carefully for valvotomy/sternotomy scars
ankylosing spondylitis (AR)

Palpation:
site and quality of apex beat
tapping (MS)
thrusting (LVH)
dextrocardia
parasternal heave (RVH)
abnormal thrills/heaves
double impulse (HOCM)

Listen with diaphragm to:
apex
axilla
left sternal edge

Listen with bell to:
left sternal edge
then turn the patient to the left
and listen at apex in held expiration

Sit patient forward:
feel for parasternal thrill
listen in inspiration and expiration
listen to the neck:
murmur radiation
carotid bruit's
feel for sacral oedema
and listen to the lung bases

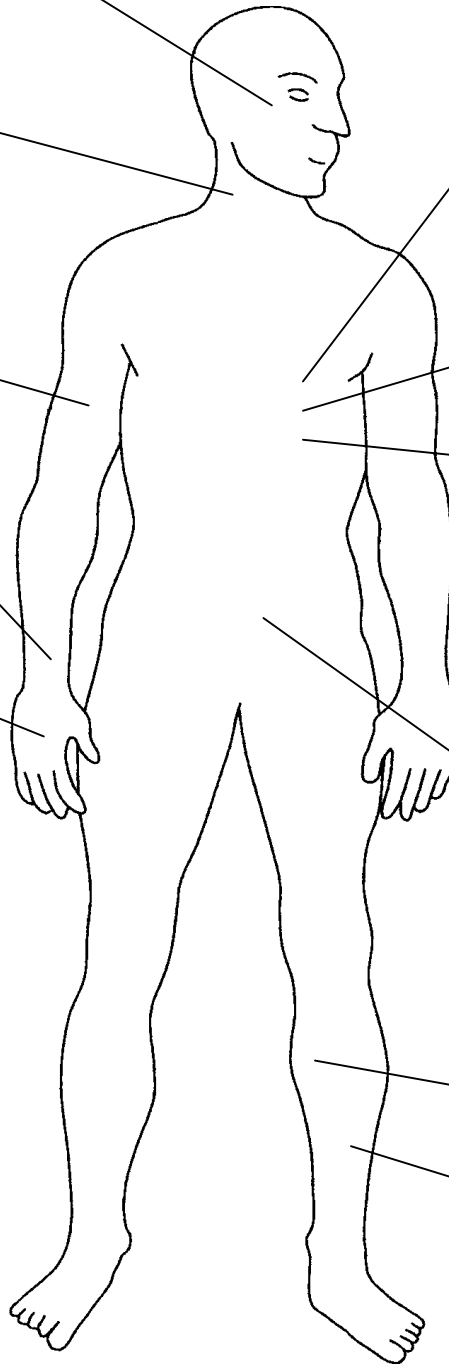
Lie the patient flat:
feel for hepatomegaly (RVF)
pulsatile hepatomegaly (TR)
splenomegaly
aortic aneurysm
ascites
renal and femoral bruits

scar from vein removal (CABG)

calf tenderness, venous thrombosis
ankle oedema
peripheral pulses
capillary filling
clubbing (if present in hands)

Introduce yourself to the patient
Optimally exposure the area to be examined
Position the patient correctly

When finished, thank the patient
Redress the patient
To complete the examination ask to examine:
temperature
radio-femoral delay
fundoscopy: hypertension
Roth spots (endocarditis)
urinalysis



Presentation of examination findings

There are two methods of presentation as covered previously at the beginning of this chapter; either a full presentation of the complete examination in order or alternatively, presenting the diagnosis first, followed by your reasoning for such a deduction. It depends on your level of confidence but if you have any doubt whatsoever you are suggested to use the complete presentation format. This demonstrates your skills of presentation to the examiners and if you do make an error when suggesting the diagnosis, they are quite likely to score you favourably if you demonstrated the correct physical signs.

Complete examination presentation

On examination of the cardiovascular system, there were no peripheral stigmata of disease, except for pallor. The pulse was 80 and irregularly irregular in atrial fibrillation with good volume. The jugular venous pressure was raised 4 cm.

On inspection of the chest, there was a midline sternotomy scar and palpation indicated a thrusting apex beat which was displaced to the sixth intercostal space in the mid axillary line. There was a parasternal heave but no added thrills.

On auscultation there was a soft first heart sound, a loud second heart sound, especially the pulmonary component and a moderate third heart sound. There was also a 4/6 pansystolic murmur heard best at the apex and radiating to the axilla, with no diastolic component. On auscultation of the lungs there are coarse crackles heard in both bases posteriorly. Examination of the legs reveals peripheral oedema of both ankles and a scar overlying the saphenous vein on the left. To complete my examination I would like to measure the blood pressure, examine the abdomen for enlargement of the liver and test the urine.

In summary this patient has signs consistent with a diagnosis of mitral incompetence which is severe in nature due to the presence of pulmonary hypertension and biventricular failure. There were no stigmata suggestive of infective endocarditis and the surgical scars suggest that the patient has had surgery for ischaemic heart disease with a vein graft to the coronary arteries.

Summary presentation

This patient has a diagnosis of severe mitral incompetence, as evidenced by; atrial fibrillation, a displaced thrusting apex beat, a soft first heart sound, loud second heart sound, a moderate third heart sound and a 4/6 pansystolic murmur heard best at the apex and radiating to the axilla.

There is also evidence of concurrent pulmonary hypertension and biventricular failure but there were no stigmata of infective endocarditis. The visible scars suggest previous coronary artery bypass surgery.

Both of these examples are for a patient with mitral incompetence, which is the most commonly encountered case when asked to examine the cardiovascular system in the short cases. Think about how you would present the findings for other cases that commonly occur in the examination.

Remember

You score marks for;

- Approach to the patient and professional manner
- Was the examination technically systematic and smooth?
- Was the presentation systematic and thorough?
- Accuracy of findings
- Interpretation of findings

Notes on examination of the cardiovascular system

In the exam setting

ATRIAL FIBRILLATION	The most common cardiac abnormality to be encountered in the short cases is mitral incompetence, which is associated with atrial fibrillation. If you find a patient with atrial fibrillation be aware that there may, be a mitral valve lesion. In finals you are quite unlikely to see a patient with pure mitral stenosis as the physical signs may be quite difficult to find.
CYANOSIS	On general inspection; the presence of central cyanosis when asked to examine the cardiovascular system should suggest the possibility of Eisenmenger's syndrome, possibly due to a VSD, ASD or PDA
BLOOD PRESSURE	The blood pressure is never examined during the short cases. You can either tell the examiner that you would measure the blood pressure at a particular point in your examination routine or mention it at the end. The latter is more favourable as it does not disrupt your routine. If the blood pressure was relevant to your diagnosis, the examiners would have told you so when introducing the patient.
RADIOFEMORAL DELAY	This can cause difficulties. Many candidates include this in their examination routines. In the setting of the short cases it necessitates palpating in the groin of the patient, who may not be embarrassed but the examiners might. In general you are not required to examine any sensitive areas (PV, PR etc) during the course of the short cases. It is best to tell the examiners that you would make such an examination rather than risk upsetting either the patient or the examiners. Attempting invasive examinations without due care and attention will most likely result in failure.
FUNDOSCOPY	This is used to look for vascular signs of hypertension and endocarditis (Roth spots). It is suggested that this is left out of your routine used for the short cases as it can take a significant length of time to complete and distract from your routine. Mention to the examiners at the end that you would also like to look in the patients eyes.

Jugular venous pressure

The JVP is examined to gain an assessment of the central venous pressure ie. that within the right atrium. To examine the JVP the patient should be positioned in a reclining position at 45° with the neck relaxed, slightly flexed and looking straight ahead. Inspect the area between the heads of sternomastoid as the internal jugular vein lies directly beneath them.. After identifying the venous pulse, the height of pulsation above the right atrium can be measured. A normal JVP is less than 4cm above the manubriosternal angle.

In patients with a very high JVP the internal jugular vein may be completely filled with the patient lying at 45° but if the patient is sat upright it may be possible to see the top of the pulsation. Even sitting the patient upright may not be adequate to assess a very high JVP and a rough estimate can be made by finding the level at which the veins on the back of the patient's hand collapse when the arm is elevated. When asked to specifically examine the jugular venous pressure diagnoses to be considered include;

Tricuspid incompetence	The incompetent valve causes a systolic pressure wave to be reflected in the venous waveform. The pulse occurs just after the c wave of the x descent and produces an exaggerated v wave in the neck.
Complete heart block	Third degree heart block produces dissociation between the atria and ventricles. Consequently the situation may occur when the atrium contracts against a closed tricuspid valve, producing a cannon a wave in the JVP waveform.
SVC obstruction	The characteristic feature is that of non-pulsatile distention of the veins in the neck.

Notes on examination of the cardiovascular system

Palpation

PULSE	The pulse can be assessed for character, volume and heart rate. Peripheral pulses that should be felt include; radial, brachial, carotid, femoral, popliteal and the pedal pulses. The speed of capillary filling after blanching can be used to assess the adequacy of the peripheral circulation in addition to the presence of pulses.
Slow rising pulse	A low volume pulse that is slow rising or plateau can be felt in aortic stenosis.
Collapsing pulse	Found with a high volume pulse that rapidly rises and falls, found in particular with aortic incompetence but also with conditions that cause a high cardiac output e.g. a hyperdynamic circulation, patent ductus arteriosus, pregnancy, severe anaemia, A-V malformations, fever, hyperthyroidism and hepatic cirrhosis. It can be felt by placing the palm of a hand over the patient's radial artery and then elevating their forearm keeping their elbow straight.
Small volume	Found in low output states such as shock, aortic stenosis and pericardial effusion.
Bisferiens pulse	A double beat pulse typical of combined aortic stenosis and incompetence.
Jerky pulse	Characteristic of hypertrophic obstructive cardiomyopathy (HOCM).
Dicrotic pulse	An apparent second impulse felt with each beat, found in hyperdynamic states.
Pulsus alternans	An alternating high and low volume pulse found in patients with left ventricular failure and it can be confirmed by using a sphygmomanometer.
APEX BEAT	The apex beat is the furthest downward and most lateral point at which the cardiac impulse is palpable. It is normally located in the fifth intercostal space in the midclavicular line on the left. Demonstrate the location to the examiner by counting down from the sternal angle. The patient should be lying straight at 45 degrees when the apex beat is examined.
Thrusting	A thrusting, heaving or sustained apex beat is found with left ventricular hypertrophy.
Tapping	This is due to a palpable first heart sound (closure of the mitral valve) and is found in mitral stenosis. The apex beat will NOT be displaced - unless there is also mitral incompetence.
Double impulse	A dyskinetic or aneurysmal segment of the left ventricle may produce a double or diffuse impulse on palpation. A double impulse can also occur in HOCM.
Absent apex beat	May be due to a pericardial effusion, obesity, emphysema or shock. It may also be due to dextrocardia where the apex will be felt on the right side.
Pericardial knock	Felt in constrictive pericarditis.
Parasternal heave	A left parasternal heave is found with right ventricular hypertrophy. A palpable second heart sound (P2) may also be found associated with pulmonary hypertension.
THRILLS	Thrills are palpable bruits; systolic in mitral incompetence, and diastolic in mitral stenosis.
Parasternal thrill	A left parasternal thrill is associated with a ventricular septal defect.
Basal thrills	Thrills heard at the base of the heart may be systolic in aortic or pulmonary stenosis and diastolic in aortic or pulmonary incompetence. It is best to interpret any thrills in combination with the auscultatory findings.

Notes on examination of the cardiovascular system

Auscultation

Auscultation of the heart should begin with the diaphragm, listening to the apex and followed by the axilla, lower left parasternal area, the right parasternal area and then the upper parasternal areas. Change to the bell and listened in the left sternal edge, the apex and then ask the patient to roll to the left and listen to the apex and axilla in held expiration (for the diastolic murmur of mitral stenosis). Ask the patient to roll back and then sit forward. Listen with the diaphragm to the upper parasternal areas and ask the patient to breath out and hold their breath. Do not forget to tell them to breath again after you have finished. With the patient still leaning forward listen to the carotid arteries for radiation and to the lung bases for signs of pulmonary oedema.

First heart sound	Mostly due to the closure of the mitral valve.
Split S1	The normal splitting of S1 is attenuated in right bundle branch block.
Second heart sound	Due to the closure of the aortic and pulmonary valves and normally the aortic component occurs first in adults and is the louder.
Split S2	Splitting of the second heart sound occurs in expiration and wide splitting occurs in left bundle branch block and pulmonary stenosis.
Fixed split S2	Fixed splitting is found in patients with an ASD and right bundle branch block.
Reversed split S2	Reversed splitting where the pulmonary component occurs before the aortic and decreases on inspiration, is found in patients with severe aortic stenosis, left bundle branch block, left ventricular failure and patent ductus arteriosus.
Third heart sound	Due to rapid ventricular filling at the time of the mitral or tricuspid valve opening and is normal in young people. It also occurs in mitral incompetence, ventricular septal defect and constrictive pericarditis.
Forth heart sound	Due to ventricular filling resulting from atrial contraction and can be heard in cardiac failure, myocardial infarction, hypertension and (HOCM) hypertrophic obstructive cardiomyopathy.

Grading of murmurs

Cardiac murmurs are divided into systolic and diastolic with loudness graded from 1-6

- 1 Just audible (in quiet surroundings)
- 2 Quiet but readily heard with a stethoscope
- 3 Moderately loud
- 4 Loud obvious murmur with a palpable thrill
- 5 Very loud, heard all over the praecordium with a pronounced thrill
- 6 Audible without the use of the stethoscope

Variation of murmurs

Louder immediately on inspiration	Pulmonary stenosis Pulmonary valve flow murmurs
Quieter immediately on inspiration	Mitral incompetence Aortic stenosis
Louder during Valsalva manoeuvre	Hypertrophic obstructive cardiomyopathy (HOCM)

Notes on examination of the cardiovascular system

Lesion	Murmur	Other physical signs
AORTIC STENOSIS	Mid systolic at apex and upper right sternal edge radiating to neck	Pale complexion Plateau pulse BP: low pulse pressure Thrusting apex beat Thrill Click Faint aortic or single reversed S2
AORTIC INCOMPETENCE	Blowing early diastolic at left sternal edge with patient sitting forward and breathing in expiration	Head nodding (De Musset's sign) Collapsing pulse BP: wide pulse pressure Carotid pulsation Thrusting displaced apex beat Thrill Femoral bruit
MITRAL STENOSIS	Rumbling mid diastolic at apex with patient rolled on left side Murmur often very localised and does not radiate	Mitral facies Peripheral cyanosis Small volume pulse AF Palpable loud S1 Opening snap (occasionally best at base)
MITRAL INCOMPETENCE	Pansystolic at apex radiates to the axilla	Thrusting displaced apex beat Thrill Third heart sound
PULMONARY STENOSIS	Mid systolic at upper left sternal edge and may radiate to the left clavicle	Cyanosis Small volume pulse JVP: large 'a' wave RV heave Split S2 with soft P2
VSD	Rough pansystolic at left sternal edge but radiates widely	No cyanosis (unless R to L shunt) Thrusting displaced apex beat Thrill
ASD	Pulmonary systolic	RV heave Fixed split S2
PDA	Continuous machinery murmur upper left sternal border (to back)	BP: wide pulse pressure Thrusting apex beat
COARCTATION OF THE AORTA	Loud rough systolic at left lung apex back and front	Hypertension in arms Radiofemoral delay Scapular and internal mammary bruits

Features of an innocent murmur

Systolic ejection murmur	Supine position best for auscultation
Short duration	Single second heart sound during respiration while standing
Soft, low-pitched and well transmitted	Normal CXR and ECG

Causes of physical signs found on cardiovascular examination

Loud first heart sound

Hyperdynamic circulation
 Fever, exercise
 Hyperthyroidism
 Mitral stenosis with mobile valve
 L to R shunts - ASD
 A-V dissociation
 Atrial myxoma
 Wolf Parkinson White syndrome

Soft first heart sound

Low cardiac output
 Rest
 Left ventricular failure
 Severe mitral incompetence
 Mitral stenosis with rigid valve
 First degree heart block
 Large pericardial effusion

Variable S1 intensity

Atrial fibrillation
 Complete heart block

Loud aortic S2

Systemic hypertension
 Tachycardia
 Dilated aortic root

Soft aortic S2

Calcific aortic stenosis

Loud pulmonary S2

Pulmonary hypertension
 ASD

Splitting of the second heart sound

Physiological: A2 pre P2 - widens on inspiration
 Paradoxical: P2 pre A2 narrows on inspiration - LBBB
 Widely split - RBBB
 Wide fixed split - ASD
 Narrow split with loud P2 - pulmonary hypertension
 Wide split with soft P2 - pulmonary stenosis
 Loud A2 - systemic hypertension
 Single S2 with inaudible A2 - calcific aortic stenosis

Fixed split S2

ASD secundum/primum
 Anomalous pulmonary venous drainage (rare)
 MISDIAGNOSIS
 Opening snap mimicking P2 (mitral stenosis)
 Mid systolic click simulating A2 (mitral valve prolapse)

Third heart sound

Normal children
 Adults up to 40 years
 High atrial pressure - LVF
 Mitral incompetence
 Tricuspid incompetence
 VSD
 Patent ductus arteriosus

Fourth heart sound

Left ventricular hypertrophy
 Ischaemic heart disease
 Hypertension
 Aortic stenosis

Systolic clicks

Pulmonary hypertension
 Mitral valve prolapse
 Bicuspid aortic valve
 Pulmonary stenosis

Venous hum

Best heard when sitting up
 More common on the right side
 Increases during respiration
 Louder in diastole
 Maximal when head turned away
 Abolished with finger pressure over internal jugular vein

Late systolic murmur

Mitral valve prolapse
 Aortic coarctation
 Pulmonary arterial stenosis
 Hypertrophic cardiomyopathy
 Papillary muscle dysfunction

Causes of physical signs found on cardiovascular examination

Signs and symptoms of heart failure

	Right ventricular failure	Left ventricular failure
SYMPTOMS	<ul style="list-style-type: none"> Tiredness Weakness Anorexia Gastrointestinal upset Fluid retention 	<ul style="list-style-type: none"> Exertional dyspnoea Orthopnoea Paroxysmal nocturnal dyspnoea often with coughing or wheezing Frothy pink haemoptysis
SIGNS	<ul style="list-style-type: none"> Dependant oedema Raised JVP Left parasternal heave May develop functional tricuspid incompetence Hepatomegaly (can be tender) Ascites Daytime oliguria Nocturia 	<ul style="list-style-type: none"> Tachycardia Pulsus alternans Cardiomegaly May develop functional mitral incompetence Gallop rhythm with third or fourth heart sound Pulmonary oedema with fine crackles at the lung bases

Often the clinical picture is that of left and right ventricular failure presenting together.

Causes of heart failure

Right ventricular failure	Left ventricular failure
<p>SECONDARY TO SYSTOLIC LOAD</p> <ul style="list-style-type: none"> Mitral stenosis Cor pulmonale Pulmonary hypertension Pulmonary embolism Pulmonary fibrosis ASD VSD <p>RARELY</p> <ul style="list-style-type: none"> Pulmonary stenosis Tricuspid incompetence Amyloidosis Atrial myxoma Endomyocardial fibrosis Constrictive pericarditis 	<p>PRESSURE OVERLOAD</p> <ul style="list-style-type: none"> Hypertension Aortic stenosis Coarctation of the aorta <p>VOLUME OVERLOAD</p> <ul style="list-style-type: none"> Aortic incompetence Mitral incompetence PDA VSD <p>MYOCARDIAL DISEASE</p> <ul style="list-style-type: none"> MI or ischaemia HOCM Myocarditis Endomyocardial fibrosis Idiopathic <p>LV RESTRICTION</p> <ul style="list-style-type: none"> Constrictive pericarditis Endomyocardial fibrosis

Causes of physical signs found on cardiovascular examination

Clubbing

CARDIOVASCULAR

Infective endocarditis
Cyanotic heart disease
Atrial myxoma
Brachial A-V fistula

RESPIRATORY

Carcinoma of the lung
Fibrosing alveolitis
Suppurative lung disease
 Bronchiectasis
 Cystic fibrosis
 Lung abscess
 Pulmonary TB
 Empyema
Asbestosis
Mesothelioma
Mediastinal tumours

GASTROINTESTINAL

Primary biliary cirrhosis
Ulcerative colitis
Crohn's disease
Cirrhosis
Coeliac disease

OTHER

Thymoma
Familial and congenital
Thyroid acropachy
Idiopathic

Hyperdynamic circulation

Exercise
Emotion: fright, anxiety
Pregnancy
Anaemia
Pyrexia
Hyperthyroidism
A-V aneurysm/fistula
Paget's disease
Beri-beri
Hepatic failure/cirrhosis
Hypercapnia
Erythroderma
Vasodilator drugs
Carcinoid syndrome
Polycythaemia rubra vera

Splinter haemorrhage

Infective endocarditis
Systemic lupus erythematosus
Psoriasis
Vasculitis
Nail trauma

Left thoracotomy scar

Previous mitral valvotomy
Previous repair of coarctation
Previous repair of PDA

Unequal radial pulses

Cervical rib
Dissection of the aorta
Proximal coarctation of the aorta
Takayasu's arteritis

Elevated JVP

Hyperdynamic circulation
Right ventricular failure
SVC obstruction (non pulsatile)
Tricuspid stenosis
Tricuspid incompetence
Pericardial effusion/tamponade
Massive pulmonary embolism
Constrictive pericarditis
Fluid overload
Very slow pulse rate

Causes of physical signs found on cardiovascular examination

Mitral incompetence

Rheumatic heart disease

Papillary muscle dysfunction
Functional due to LV dilatation
Trauma (mitral valvotomy)
Ischaemic heart disease
Infective endocarditis
Leaking prosthetic valve

RARELY

Rheumatoid arthritis
SLE
Hurler's syndrome
Endocardial fibroelastosis
Osteogenesis imperfecta
Floppy mitral valve syndrome
Marfan's syndrome
Ehlers-Danlos syndrome
HOCM
Congenital
Ostium primum ASD

Aortic incompetence

Rheumatic heart disease

Functional aortic incompetence
Hypertension
Marfan's syndrome
Aortic dissection
Hypertension
Marfan's syndrome
Trauma
Infective endocarditis
Prosthetic valve malfunction

RARELY

Arthritides
Rheumatoid arthritis
Ankylosing spondylitis
Reiter's syndrome
SLE
Congenital
Syphilis

Tricuspid incompetence

Functional due to RV dilatation
Mitral stenosis
Eisenmenger's syndrome
Papillary muscle rupture
Infective endocarditis
(especially in drug addicts)
Carcinoid syndrome
Rheumatic (with MV disease)
Endomyocardial fibrosis
Congenital - Ebstein's anomaly

Pulmonary incompetence

Pulmonary hypertension
Functional: Graham-Steell
Congenital
Post valvotomy
Infective endocarditis

Mitral stenosis

Rheumatic heart disease

RARELY

Lutembacher's syndrome
(Mitral stenosis + ASD)
Hurler's syndrome
Endomyocardial fibrosis

Aortic stenosis

Congenital - bicuspid valve
Rheumatic heart disease
Degenerative with calcification

RARELY

Prosthetic valve malfunction
Idiopathic hypercalcaemia
Idiopathic supra-valvar AS
HOCM (subvalvar AS)

Tricuspid stenosis

ALL VERY RARE
Rheumatic heart disease
Carcinoid syndrome

Pulmonary stenosis

ALL VERY RARE
Mostly congenital
Carcinoid syndrome
Rheumatic heart disease
Fallot's tetralogy

Causes of physical signs found on cardiovascular examination

Pericardial effusion

INFECTIVE

Viral pericarditis
Bacterial pericarditis
 Streptococcus
 Pneumococcus
 Tuberculous

MYOCARDIAL INFARCTION

Peri-infarct pericarditis
Cardiac rupture
Dressler's syndrome

MALIGNANT

Secondary
Primary (rare)
Leukaemia

OTHER

Acute rheumatic fever
Rheumatoid arthritis
Trauma
Myxoedema
Post cardiac surgery

HAEMOPERICARDIUM

Trauma - penetrating and non-penetrating
Dissecting aortic aneurysm
Bleeding diathesis
Leukaemia
Severe uraemia
Ventricular rupture
Myxoedema

Acute myocarditis

Infections

Coxsackie B
Echo virus
Influenza
Chickenpox
Diphtheria
Clostridium
Staphylococcal
Chagas' disease
Toxoplasmosis
Rickettsial

Acute rheumatic fever

Connective tissue disorders

Serum sickness
Drugs
 Cyclophosphamide
 Daunorubicin

Idiopathic

Pericarditis

Acute idiopathic

Infections
 Viral
 Bacterial: TB
 Fungal
Myocardial infarction
 Acute
 Dressler's syndrome
Malignancy
Uraemia
Trauma
Collagen vascular disease
 SLE
 Rheumatoid arthritis
Rheumatic fever
Post cardiomy syndrome
Hypothyroidism
Radiotherapy
Drugs
 Hydralazine
 Methysergide
 Procainamide
Serum sickness
Chylopericardium
Acute aortic dissection
Hurler's syndrome
Endomyocardial fibrosis
Reiter's disease
Myxoedema

Indications for heart-lung transplantation

PULMONARY HYPERTENSION

secondary to primary pulmonary hypertension
secondary to congenital heart disease (Eisenmenger's)
secondary to cystic fibrosis

Signs of rejection

Fever (early sign)
CXR: cardiomegaly
ECG: conduction disturbances
 reduced QRS voltage
Cardiac failure (late sign)

Relative contraindications to heart transplantation

Currently acceptable quality of life
Age greater than 50
Severe pulmonary hypertension (heart-lung)
Past history of thromboembolism
Insulin dependant diabetes
renal or hepatic insufficiency
Major systemic or psychiatric illness
Positive cytotoxic match with the donor organ.

Causes of rhythm abnormalities

Atrial fibrillation

Mitral valve disease
Myocardial infarction
Hyperthyroidism
Ischaemic heart disease
Hypertension
Sick sinus syndrome
Atrial septal defect
Idiopathic
Constrictive pericarditis
Cardiomyopathy
Pulmonary embolism

RARELY

Atrial myxoma
Chest surgery
Infective endocarditis
Myocarditis
Haemochromatosis
Carcinoma of the lung
Acute viral infection
Intracardiac metastasis
Electrocution
Digoxin toxicity (VERY rare)

Sinus tachycardia

Hyperdynamic circulation
Exercise
Anxiety
Fever
Hyperthyroidism
Acute severe haemorrhage
Congestive cardiac failure
Vasodilator drugs
Hydralazine
Nifedipine
Other drugs
Adrenaline
Atropine
Nitrates
Acute MI
Severe anaemia
Constrictive pericarditis
A-V shunts

Sinus bradycardia

Sleep
Athletes
Post viral infections
Sick sinus syndrome
Congenital
Drugs
Beta blockers
Digoxin
Early MI esp. inferior
Hypothermia
Hypothyroidism
Raised intracranial pressure
Obstructive jaundice
Rapid rise in blood pressure
Vomiting -
(increased vagal tone)
Hypopituitarism

Assessment of cardiorespiratory function

NYHA Grade I	dyspnoeic only on extreme exertion
NYHA Grade II	dyspnoeic walking up hills or stairs
NYHA Grade III	dyspnoeic on minimal exertion on flat ground
NYHA Grade IV	dyspnoeic at rest

(New York Heart Association criteria)

Assessment of chest pain

Grade I	angina only on strenuous or prolonged exertion
Grade II	angina climbing two flights of stairs
Grade III	angina on minimal exertion on flat ground
Grade IV	angina at rest

(modified Canadian Cardiovascular Society criteria)

Chest pain: how to describe it

When?

First onset
Duration of individual episodes
Periodicity

Where?

Site of origin
Radiation
Effect of different postures

How?

Severity
Nature
Exacerbating and relieving factors

Learning objectives for cardiovascular examination

1. Practise examination of the cardiovascular system using the previous outline diagram for reference. Ask someone to act as an examiner and criticise your approach.
2. Understand how to measure the blood pressure and the relevance of abnormalities that can be detected.
3. Understand the significance of peripheral signs associated with cardiovascular disease.
4. How do you measure the jugular venous pressure (JVP)? Understand the different waveforms that may be found and their diagnostic significance.
5. Learn the cardiovascular signs associated with the following;

Clubbing	Marfan's syndrome
Atrial fibrillation	Down's syndrome
Signs of prosthetic valves	Cushing's syndrome
Raised JVP	Myxoedema
Left ventricular failure	Collagen vascular disorders
Pulmonary oedema	Infective endocarditis
Pulmonary hypertension	
Peripheral oedema	
6. Try to see patients with the following conditions before the examinations;

Mitral incompetence	Mixed mitral valve disease
Aortic incompetence	Mixed aortic valve disease
Tricuspid incompetence	Mixed mitral and aortic valve disease
Aortic stenosis	Mitral stenosis
Infective endocarditis	Left ventricular failure
Eisenmenger's syndrome	Recent myocardial infarction
Atrial septal defect	Complete heart block
Ventricular septal defect	Pulmonary hypertension
Dextrocardia	Paroxysmal tachycardia
Coarctation of the aorta	
Abdominal aortic aneurysm	
Carotid body tumour/carotid aneurysm	
7. Where on the body can you hear bruits ? What diagnostic significance would they have if found ?
8. Learn the ECG findings of;
 - Sinus bradycardia
 - Narrow complex tachycardia (SVT)
 - Broad complex tachycardia (VT or aberrant conduction)
 - Left and right bundle branch block
 - Changes of acute and old myocardial infarction
 - First degree, second degree and complete heart block
 - Ventricular fibrillation
9. Learn the British Resuscitation Council guidelines for cardiopulmonary resuscitation.
10. Practise the examination routines again until you are confident in your approach and the method looks slick and impressive. You should keep a steady rhythm during the assessment of the patient rather than pausing continually, which will give the examiners the opportunity to stop you and ask a question.

Space for further notes on examination of the cardiovascular system